

# Hepatitis B Virus-Associated Focal and Segmental Glomerular Sclerosis: A Rare Case of Tip Variant

Amel Harzallah<sup>1,2,3\*</sup>, Karray Rahma<sup>1,3</sup>, Hedri Hafedh<sup>1,2,3</sup>, Hajji Mariem<sup>1,2,3</sup>, Goucha Rim<sup>2,3</sup>, Ben Hamida Fethi<sup>1,2,3</sup>, Gorsane Imen<sup>1,2,3</sup> and Abderrahim Ezzeddine<sup>1,2,3</sup>

<sup>1</sup>Department of Medicine A, Charles Nicolle Hospital, Tunis, Tunisia

<sup>2</sup>Laboratory of Renal Pathology LR00SP01, Charles Nicolle Hospital, Tunis, Tunisia

<sup>3</sup>Faculty of Medicine of Tunis, University of Tunis El Manar, Tunis, Tunisia



\*Corresponding author: Amel Harzallah, Department of Medicine A, Charles Nicolle Hospital, Tunis, Tunisia.

Tel: +216-98559342; E-mail: amel\_harz@yahoo.fr



Article Type: Case Report

Compiled date: May 13, 2022

Volume: 3

Issue: 4

Journal Name: Clinical Case Reports Journal

Publisher: Infact Publications LLC

Journal Short Name: Clin Case Rep J

Article ID: INF1000180

Copyright: © 2022 Amel Harzallah. This is an open access article distributed under the terms of the Creative Commons Attribution 4.0 International License (CC BY-4.0).



**Keywords:** Hepatitis B virus; Glomerulonephritis; Focal segmental glomerular sclerosis



**Cite this article:** Harzallah A, Karray R, Hafedh H, Mariem H, Goucha R, Hamida BF, et al. Hepatitis B virus-associated focal and segmental glomerular sclerosis: a rare case of tip variant. Clin Case Rep J. 2022;3(4):1–5.

## Abstract

**Introduction:** Glomerular involvement is a common renal complication associated with Hepatitis B infection. Although membranous nephropathy is the pathology most frequently encountered, other glomerular diseases, such as focal and segmental glomerulosclerosis (FSGS), are rare. We report a rare case of hepatitis B-associated FSGS.

**Case Report:** A 48-year-old man, an inactive carrier of HBV from 2013, presented a 1-month history of generalized edema. Clinical examination revealed edema of the lower extremities associated with reduced breathing sounds at the base of the lung. The urine dipstick showed hematuria (++) with proteinuria (+++). Laboratory data revealed features of nephrotic syndrome (serum albumin, 18 g/l; proteinuria, 19 g/day) and acute kidney injury (serum creatinine, 124  $\mu\text{mol/l}$ ). He had a normal hepatic check. Quantitative and qualitative HBV DNA was at  $2.84 \times 10^2$  UI/ml. The screening for other infections was negative. Renal histology showed an FSGS-type 'tip lesion' associated with tubular lesions. Treatment combined a loop diuretic, angiotensin-converting enzyme inhibitor, oral anticoagulation, and antiviral treatment with Entecavir (0.5 mg/day). After two months of antiviral treatment, his biological markers improved with undetectable viral DNA.

**Conclusions:** FSGS is a podocytopathy that can be rarely associated with an active viral infection such as HBV. Its management differs from primary FSGS, which is based on nucleotide analogs with good responses.

## Abbreviations

HBV: Hepatitis B Virus; FSGS: Focal and Segmental Glomerulonephritis; HIV: Human Immunodeficiency Virus; BMI: Body Mass Index; STAT: Transcription Factors Located in the Cytoplasm.

## Introduction

Chronic Hepatitis B Virus (HBV) infection is the most common chronic viral infection in the world, affecting more than 400 million people, more than double the prevalence of chronic Human Immunodeficiency Virus (HIV) and hepatitis C carriers combined [1]. Renal disease may occur in 3% to 5% of patients with chronic HBV infection [2]. HBV is associated with a broad spectrum of renal diseases such as membranous glomerulonephritis, membranoproliferative glomerulonephritis, polyarteritis nodosa, and direct focal and segmental glomerulonephritis (FSGS). The most common HBV-related renal disease is membranous

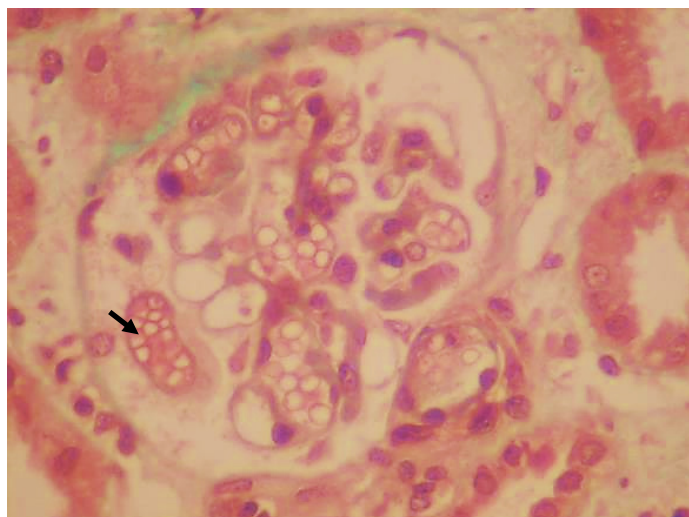
glomerulonephritis. The association of FSGS with HBV is rare, with only a few cases described in the literature. We report herein a further case of hepatitis B infection associated with FSGS.

**Case Presentation**

A 48-year-old man investigating nephrotic syndrome presented a 1-month history of progressive generalized edema. He had a history of inactive carriage of HBV for five years. Hepatitis B was discovered following a blood donation. On this date, the hepatitis B markers showed positive Hepatitis B surface antigen (Hbs Ag), positive anti-Hbc antibodies, and undetectable viral DNA.

The patient reported no use of medications, no fever or skin lesions, and no family history of nephropathy. Clinical examination revealed lower extremity edema with reduced breath sounds in the bases of the lung. The patient weighed 67 kg, had a height of 1.78 m (BMI 21.1), and was normotensive. The urine dipstick showed hematuria (++) with proteinuria (+++). Laboratory data (Table 1) showed serum creatinine: 124 μmol/L (reference range 54 μmol/L–95 μmol/L); total cholesterol: 7.17 mmol/L (reference range 3.2 mmol/L–5.18 mmol/L) and serum albumin: 1.8 g/dL (reference range 3.5 g/dL–5.0 g/dL). His proteinuria was 19 g/day, and urinalysis had 10,000 leucocytes and 20,000 erythrocytes. Serology revealed HBsAg positivity. HBV DNA analysis showed 2.84 x 10<sup>2</sup> UI/ml. The screening for other viral infections such as Hepatitis C Virus, HIV, Epstein Barr Virus, and Cytomegalovirus was negative. Serum complement levels were normal.

The patient underwent a renal biopsy. There were 21 glomeruli for analysis by light microscopy. The mesangial matrix was mildly increased. Some glomeruli had podocyte hypertrophy and podocyte detachment in the urinary space (Figure 1A), with a glomerulus showing a tip lesion (Figure 1B). Some tubes had a vacuolated or flattened epithelium. In addition, there was the presence of mitosis (Figure 1C) and inclusions in some epithelial cell nuclei (Figure 1D) and the presence of hyaline and hematic casts (Figure 1E). There was no tubular atrophy; neither tubular necrosis nor interstitial fibrosis was present.



**Figure 1A:** Glomeruli with podocyte hypertrophy and podocyte detachment in the urinary space.

Small-caliber vessels were the seat of parietal hyaline deposits in the vascular compartment with one clogged arteriole, and some vessels of larger calibers presented fibrous parietal thickening (Figure 1F).

Immunofluorescence analysis showed mesangial IgM deposits and was negative for IgA and IgG. Unfortunately, electron microscopy was not performed because it is unavailable in our hospital.

After ruling out other causes of secondary FSGS, he was diagnosed with hepatitis B-associated FSGS.

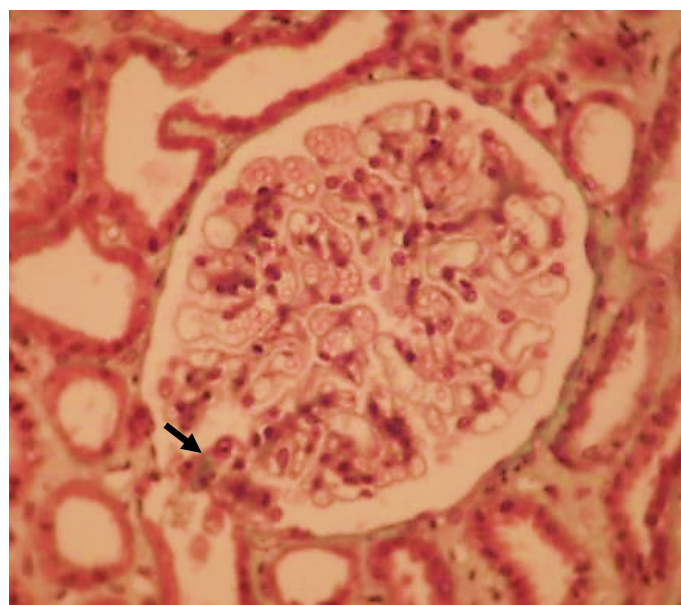
The patient was started on Captopril, furosemide, and oral anticoagulation with Acenocoumarin. He also received antiviral treatment with Entecavir at a 0.5 mg/day dose. Immunosuppressive therapy was not applied.

After two months, the features of the nephrotic syndrome resolved (Table 1), and proteinuria decreased to 0.18 g/day. Viral DNA was undetectable on analysis. Currently, the patient is well on clinical follow-up. Unfortunately, he is still in remission and continues on Entecavir for two years.

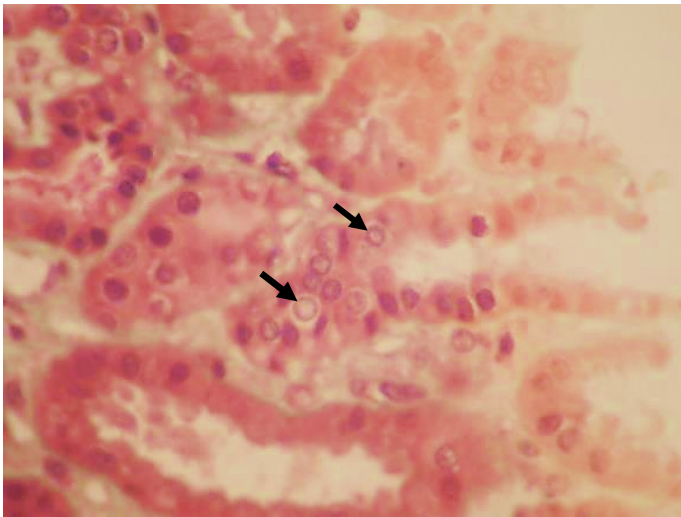
**Table 1:** Biological characteristics of our patient.

Parameters	Value at diagnosis	Value after 2 months
Albumin (g/dL)	1.8	4.4
Urinary protein (g/day)	19	0.18
Serum creatinine (μmol/l)	124	87
Aspartate aminotransferase (UI/L)	25	16
Alanine aminotransferase (UI/L)	27	12
Total bilirubin (mmol/L)	12	12
Hemoglobin (g/dl)	12.1	14.4
Mean corpuscular volume	88	86
Prothrombin time	85%	80%
HBV DNA (UI/ml)	2.84 x 10 <sup>2</sup>	< 10

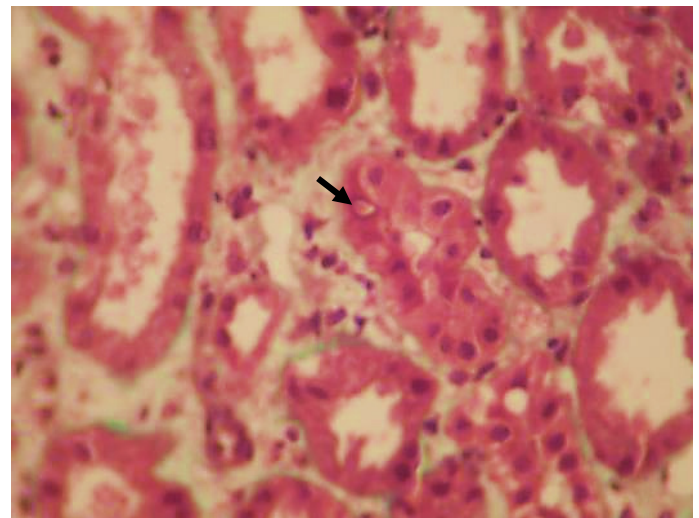
**HBV:** Hepatitis B virus.



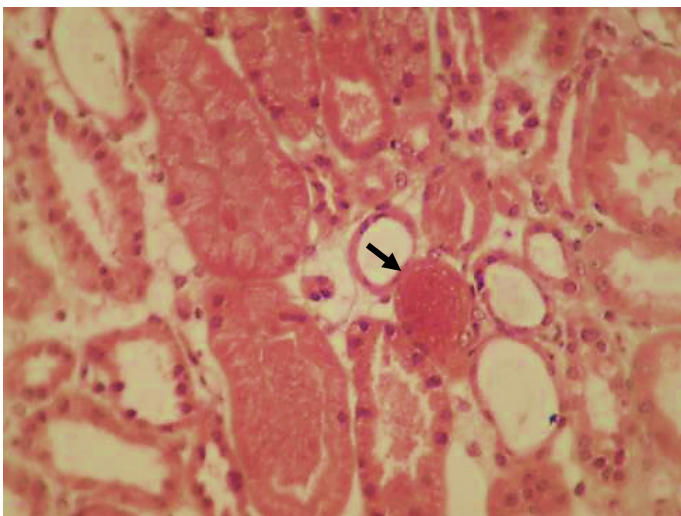
**Figure 1B:** Glomerulus showing tip lesion.



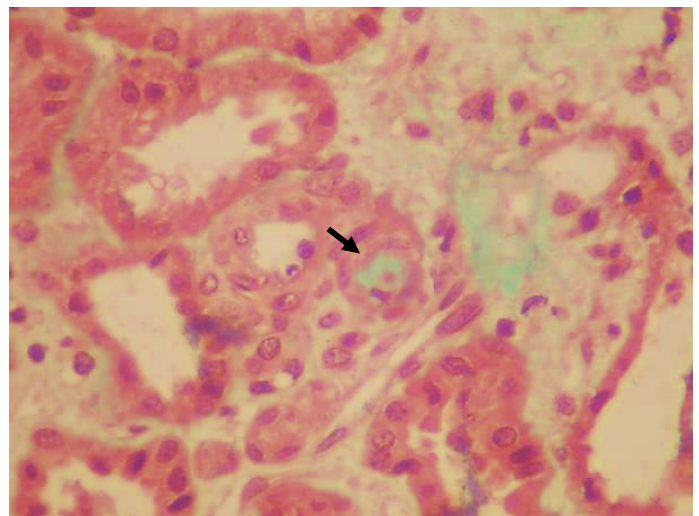
**Figure 1C:** Presence of mitosis in epithelial cell nuclei.



**Figure 1D:** Presence of inclusion in epithelial cell nuclei.



**Figure 1E:** Presence of hematic casts.



**Figure 1F:** Presence of one clogged arteriole.

## Discussion

HBV-associated nephropathy is one of the most common extrahepatic manifestations of HBV infection extrahepatic manifestations. Several morphological patterns of renal disease, including membranous nephropathy, membranoproliferative glomerulonephritis, mesangial proliferative glomerulonephritis, minimal change disease, IgA nephropathy, and rarely FSGS, have been described in association with HBV infection [3]. In adults, chronic HBV infection is usually related to membranous nephropathy. Some reports in the literature have described an association between FSGS and HBV (Table 2).

The tip variant FSGS is extremely rare, and, to our knowledge, few cases have been reported in association with chronic HBV infection. The pathogenesis of HBV-related nephropathy is not fully understood. Immune complex-mediated mechanisms are thought to play a central role which could explain the occurrence of membranous nephropathy, membranoproliferative glomerulonephritis, and IgA nephropathy [3]. Immune deposits may be formed from the deposition of an IgG immune complex with one or more viral antigens or with the de novo formation of an immune complex after the deposition of the circulating antigen

in the basement membrane first, followed by deposition of the circulating antibody [4].

In addition to immune complex-mediated damage in the HBV-associated FSGS, other pathogenic pathways of podocyte damage and loss are also associated [3]. Some authors thought that HBV injures podocytes like HIV. Sakai et al. supported this hypothesis by identifying HBV DNA in the podocyte (real-time PCR method) [5]. Some research in children indicated that the number and density of podocytes decreased significantly in patients with HBV glomerulonephritis. This was usually accompanied by increases in urinary protein [6]. A recent study suggests that the HBV-produced X protein decreases nephrin expression and induces podocyte apoptosis by activating STAT3 (transcription factor located in the cytoplasm) [7]. Like our patient, all the other cases reported in the literature had active HBV infection [8]. Concerning these data, direct virus infection seems to play an essential role in the occurrence of HBV-FSGS. The criteria to link the acute onset of FSGS to acute viral infections are very complex and difficult.

The diagnosis of virus-related nephropathy is based mainly on detecting specific antigens in blood or any other body sample

and the identification of viral antigens in glomerular structures and the clinical and histological picture. In our case, detection of viral antigens was not available. Therefore, the diagnosis of FSGS-HBV was made retrospectively after remission of nephrotic syndrome with viral treatment alone and after exclusion of other

differential diagnoses. Epidemiologically, most of the patients in the previous studies were young men (mean age of 18.6 years), while our patient was the oldest one (48 years). They all presented with nephrotic proteinuria (Table 2).

**Table 2:** Literature review of focal and segmental glomerulosclerosis associated with HBV infection.

Author/ year	Age (year) / Gender	Clinical signs	Diagnosis	Treatment	Evolution
Sakallioğlu [10]/2005	8/Male	Pure NS resistant to IT	HBV serologic test.	Lamivudine	8/Male Pure NS resistant to IT HBV serologic test Lamivudine.
Khaira [3]/2009 (2 cases)	15/Male (the 2 boys)	NS	HBsAg in the renal tissue: Focal deposits of HBsAg in the glomerular capillary wall and mesangium. Focal deposits of hepatitis B core antigen (HBcAg) in the cytoplasm of tubular epithelial cells.	Lamivudine	*CR of the NS HBV DNA: undetectable.
Sakai [5]/2011	33/Male	NS + mild renal failure	HBV-DNA in urinary podocytes (real-time PCR methods).	Lamivudine (2 months) followed by steroids.	No remission
				Entecavir (2 months)	*CR of the NS Renal biopsy: no obvious FSGS lesions in > 20 glomeruli.
Javaid [11]/2018	22/Female	Pure NS		Entecavir	CR (5 months)
Takaki [12]/2002	52/Male	NS		Prednisolone 1 mg/day + LDL apheresis.	Proteinuria < 1 g/gcr

**HBV:** Hepatitis B Virus; **NS:** Nephrotic Syndrome; **CR:** Complete Remission; **IT:** Immunosuppressive Therapy.

**\*Complete remission of nephrotic syndrome:** Urinary protein < 0.7 g/day or 1 + protein on urine dipstick for 3 consecutive days.

The management of FSGS-HBV is unclear. The recent guidelines do not provide specific recommendations on this entity. However, they recommend that patients with replicative HBV infection (defined by HBV DNA levels > 2000 IU/ml) and glomerulonephritis receive treatment with nucleoside analogs as recommended for the general population by standard clinical practice guidelines for HBV infection [9]. In fact, in the case of glomerulonephritis related to HBV infection, immunosuppressive treatment can be very harmful. It may enhance viral replication and flare-up hepatic disease. Lamivudine has been the most widely used agent in nephrotic patients with an FSGS with good clinical response. However, lamivudine monotherapy can lead to a somatic mutation of HBV that leads to the development of resistance [4]. Entecavir and tenofovir are now preferred as first-line therapy [4], as this was the case in our patient.

## Conclusions

Focal and Segmental Glomerulonephritis-Hepatitis B Virus (FSGS-HBV) is a rare disease that complicates an active viral infection. It usually affects young male patients. The clinical feature is nephrotic proteinuria. The management is different from primary FSGS. In case of resistance, it is based on nucleotide analogs, including lamivudine or entecavir. Remission is usually obtained after an average of two months (the time required to inhibit viral replication). For this reason, patients with proteinuria suggesting a glomerular disease should be tested for HBV infection.

## Conflict of Interest

The authors declare no potential conflicts of interest with respect to the research, authorship, and/or publication of this article. Informed consent was obtained for this publication.

## References

1. Zampino R, Boemio A, Sagnelli C, Alessio L, Adinolfi LE, Sagnelli E, et al. Hepatitis B virus burden in developing countries. *World J Gastroenterol*. 2015;21(42):11941–11953.
2. Gupta A, Quigg RJ. Glomerular Diseases Associated with Hepatitis B and C. *Adv Chronic Kidney Dis*. 2015;22(5):343–351.
3. Khaira A, Upadhyay BK, Sharma A, Das P, Mahajan S, Makhariya G, et al. Hepatitis B virus-associated focal and segmental glomerulosclerosis: report of two cases and review of literature. *Clin Exp Nephrol*. 2009;13(4):373–377.
4. Kupin WL. Viral-Associated GN. *Clin J Am Soc Nephrol*. 2017;12:1529–1533.
5. Sakai K, Morito N, Usui J, Hagiwara M, Hiwatashi A, Fukuda K, et al. Focal segmental glomerulosclerosis as a complication of hepatitis B virus infection. *Nephrol Dial Transplant*. 2011;26(1):371–373.
6. Zhang Y, Zhou J, Wang H. Podocyte depletion in children with hepatitis B virus-associated membranous nephropathy. *Zhonghua Er KeZaZhi*. 2007;45(5):344–348.
7. Lei XY, Chen XX, Sun YH, Gao MD, Hu XX, Suo YH. Hepatitis B virus X protein decreases nephrin expression and induces podocyte apoptosis via activating STAT3. *Exp Ther Med*. 2019;17(5):4223–4229.
8. Khedmat H, Taheri S. Associations of various histological morphologies of renal involvement in hepatitis B infection: Analysis of 118 subjects. *Saudi J Kidney Dis Transpl*. 2010;21(5):964–966.
9. KDIGO. Clinical practice guideline on glomerular diseases [Internet]. New York: KDIGO; 2020.
10. Sakallioğlu O, Gök F, Kalman S, Kurekci AE, Gunhan O, Gökçay E. Hepatitis B complicated focal segmental glomerulosclerosis. *J Nephrol*. 2005;18(4):433–435.
11. Javaid MM, Khatri P, Subramanian S. Should antiviral monotherapy with nucleotide analogs be the primary treatment option for focal segmental glomerulosclerosis-related nephrotic syndrome in chronic hepatitis B infection? *Saudi J Kidney Dis Transpl*. 2018;29(3):714–718.
12. Takaki A, Nakatsuka A, Satou C, Iwata Y, Ikeda H, Fukushima M. A case of focal segmental glomerulosclerosis (FSGS) complicated with chronic hepatitis B and treated with steroid and LDL apheresis. *Nippon Jinzo Gakkai Shi*. 2002;44:806–812.