

# Combined Picosecond Laser Tattoo Removal with an Acoustic Shock Wave Device: A Case Series

Ricardo Galvan Garcia\* and In Lu Chen

Department of Dermatosurgery, Dermatology Hospital,  
Jalisco, Mexico



\*Corresponding author: Ricardo Galvan Garcia, Department of Dermatosurgery, Dermatology Hospital, Lopez Cotilla 2261 Colonia Arcos Vallarta, C.P. 44130. Guadalajara, Jalisco, Mexico. Tel: +52-33-36163215;  
E-mail: doctorricardogalvan@hotmail.com



Article Type: Case Report

Compiled date: February 11, 2022

Volume: 3

Issue: 1

Journal Name: Clinical Case Reports Journal

Publisher: Infact Publications LLC


Journal Short Name: Clin Case Rep J

Article ID: INF1000135

Copyright: © 2022 Ricardo Galvan Garcia. This is an open access article distributed under the terms of the Creative Commons Attribution 4.0 International License (CC BY-4.0).



Keywords: Tattoo removal; Picosecond laser; Acoustic pulse; Acoustic shock wave



Cite this article: Garcia RG, Chen IL. Combined picosecond laser tattoo removal with an acoustic shock wave device: a case series. Clin Case Rep J. 2022;3(1):1–6.

## Abstract

Optimal laser tattoo removal in fewer sessions has been consistently investigated. As a result, dermatologists and laser surgeons have been leading the way to develop techniques and methods to remove tattoos in the fastest and safest possible way effectively.

Acoustic Shock Wave Therapy has been recently described as an adjuvant in enhancing tattoo clearance by increasing lymphatic drainage and increasing metabolic activity in the treated area, thereby accelerating the clearance of dermal pigment vacuoles produced by picosecond and Q-switched lasers.

We present a case series of 4 patients who underwent 1 to 3 combined sessions of picosecond laser and acoustic shock wave therapy on monthly intervals for tattoo removal, resulting in a faster clearing of the lesions without major side effects.

## Introduction

For decades, the removal of both professional and semi-professional tattoos has been sought in many different ways: from the salabrasion method published by Gary Manchester in 1973 [1] to the use of tannic acid in 1991 [2] and silver nitrate in 1995 [3], with highly variable results.

With the introduction of Q-switched laser devices and, more recently, picosecond lasers, better outcomes are achieved, and side effects are less frequent [4,5]. In most cases, many sessions are required, and the time needed between sessions is the main factor that makes patients quit the treatment. Therefore, optimal laser tattoo removal in fewer sessions has been consistently investigated. Dermatologists and laser surgeons have been leading the way to developing techniques and methods to remove tattoos in the fastest and safest possible way effectively.

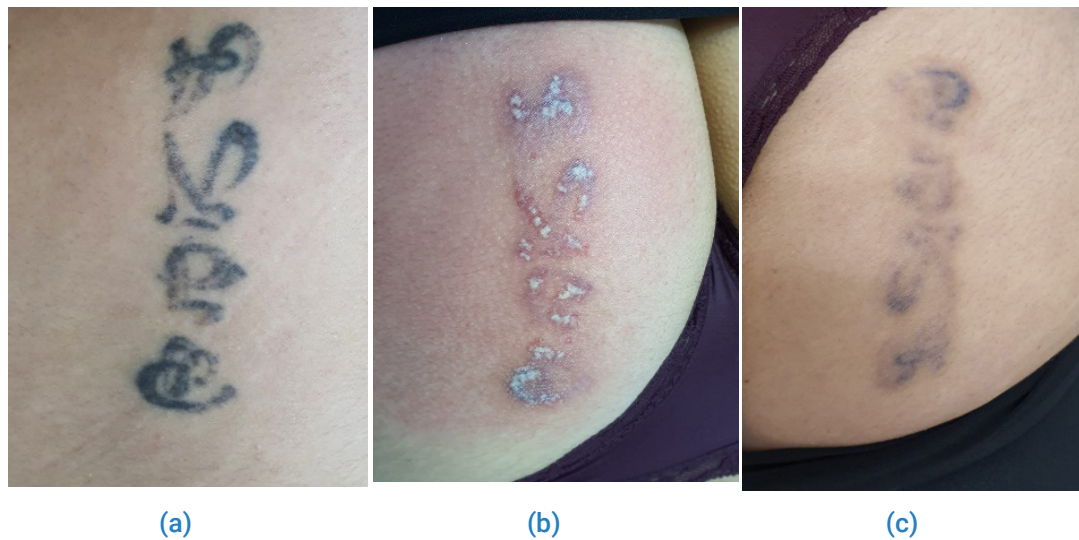Acoustic Shock Wave Therapy has been recently described to be an adjuvant in enhancing tattoo clearance by increasing lymphatic drainage and increasing metabolic activity in the treated area, thereby accelerating the clearance of dermal pigment vacuoles produced by picosecond and Q-switched lasers [6,7].

We present a case series of 4 patients successfully treated with combined sessions of a 1064 nm Nd: YAG picosecond laser (Discovery Pico, Quanta System, Milan, Italy) and acoustic shock wave therapy (X-Wave, BTL Aesthetics, Czech Republic) for accelerated tattoo removal, without major side effects.

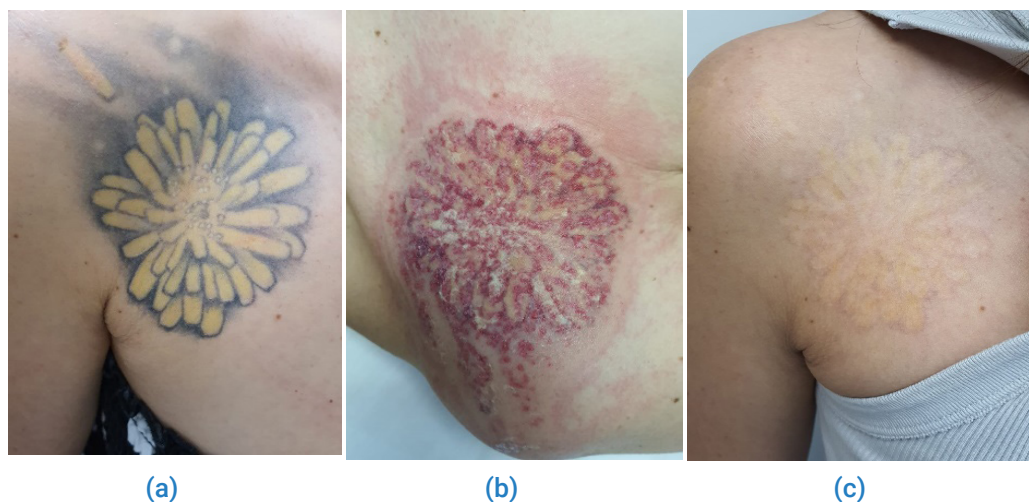
## Case Presentations

**Case 1:** A 38-year-old woman came to our clinic with a professional monochromatic black tattoo of 15 years of evolution on the right side of her buttock. To this date, she has not received previous treatments for tattoo removal. A test was performed on a small area for evaluating the skin reaction. The lesion was treated with three combined sessions of 1064 nm Nd: YAG Picosecond laser and Acoustic Shock Wave one month apart. The following parameters were used: 1064 nm wavelength, 3 J/cm<sup>2</sup>, spot size 3 mm, 450 picoseconds, 10 Hz, two passes, one focused and one defocused, followed immediately by two passes of acoustic shock wave 2.2 Bar, 14 Hz, 2400 shots in total. Any discomfort was reduced with contact cooling. The patient reported minor side effects and described a significant analgesic effect during the use of the acoustic shock wave. One month after the last session, we could observe a remarkable fading of the tattoo (Figure 1).

**Case 2:** A 35-year-old woman had a large professional polychromatic black/grey and yellow tattoo of 5 years on her right shoulder. She had not received previous tattoo removal treatments. The lesion was treated with two monthly combined sessions of Picosecond laser and Acoustic Shock Wave with the following parameters: 1064 nm wavelength, 3 J/cm<sup>2</sup>, spot size 3 mm, 450 picoseconds, 10 Hz, two passes, one focused and one defocused on the black and grey ink and 532 nm wavelength, 1.3 J/cm<sup>2</sup>, spot size 3 mm, 370 picoseconds, 10 Hz, one pass, focused on the yellow ink. Immediately after, we applied two acoustic shock wave therapy passes with the following parameters: 2 Bar, 14 Hz, 1000 total shots. Any discomfort was reduced with contact cooling. The patient did not refer to any significant side effects. One month after two sessions, the lesion had almost completely disappeared. The patient was satisfied with these results and decided to stop the treatment (Figure 2).



**Figure 1:** a: A professional monochromatic black tattoo on the right side of the buttock; b: The immediate end point after picosecond laser treatment; c: The same lesion 1 month later, after 3 combined sessions of picosecond laser and acoustic shock wave.

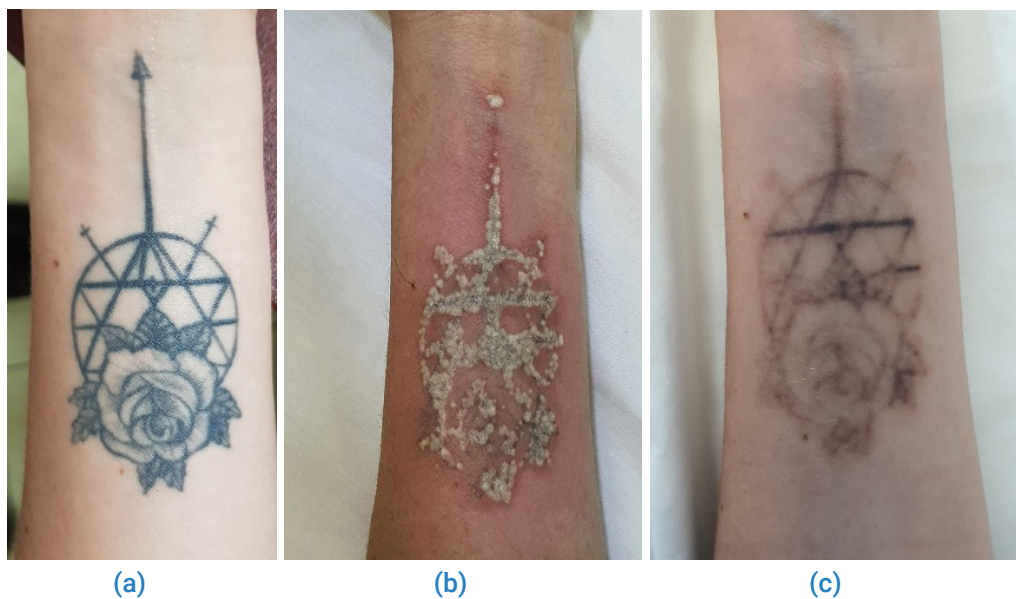


**Figure 2:** a: A professional polychromatic black, grey and yellow tattoo on the right side of the shoulder; b: The immediate end point after picosecond laser treatment; c: The same lesion 1 month later, after 2 combined sessions of picosecond laser and acoustic shock wave.

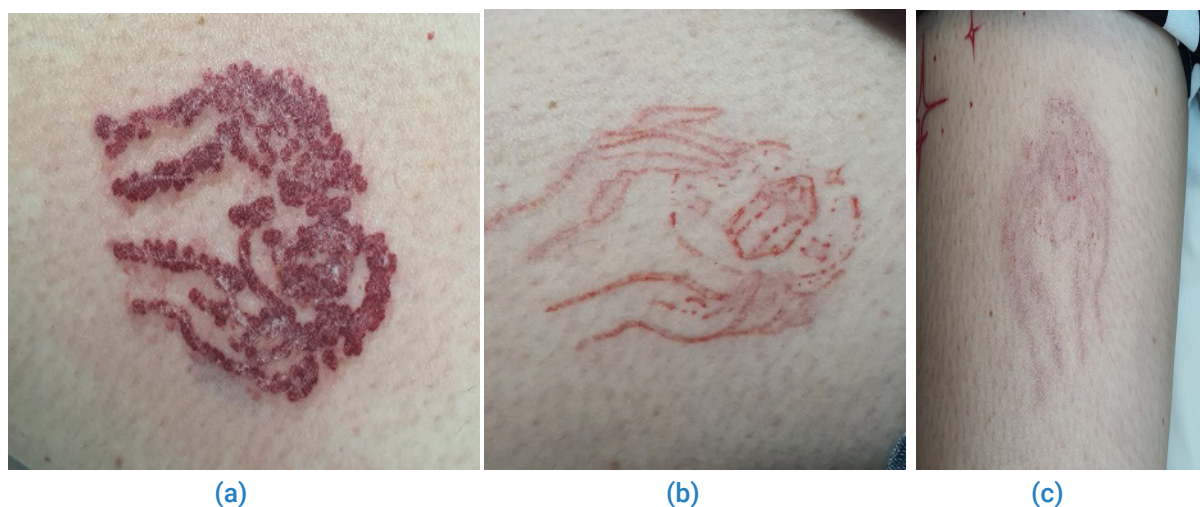**Case 3:** A 33-year-old woman came to our clinic with a professional monochromatic black tattoo of 3 years of evolution on her anterior right forearm. She had not received previous treatments. The tattoo was treated with three combined Picosecond laser and Acoustic Shock Wave sessions one month apart. The following parameters were used: 1064 nm wavelength, 3.5 J/cm<sup>2</sup>, spot size 3 mm, 450 picoseconds, 10 Hz, two passes, one focused and one defocused, followed immediately by two passes of acoustic shock wave 2 Bar, 14 Hz, 1200 shots in total. The patient reported minor side effects and referred to a significant analgesic effect during the use of the acoustic shock wave. However, after one month of the last session, the lesion presented significant tattoo fading (Figure 3).

**Case 4:** A 28-year-old female patient came to our clinic to remove

a monochromatic red tattoo of 3 years of evolution on the left side of her anterior thigh. She had not received previous treatments. The lesion was treated with one single combined session with the following parameters: 694 nm wavelength, 3.6 J/cm<sup>2</sup>, Spot size 3 mm, 30 nanoseconds, 3 Hz, one pass, focused, followed by 532 nm wavelength, 1.3 J/cm<sup>2</sup>, Spot size 3 mm, 370 picoseconds, 10 Hz, one pass, focused. Immediately after the laser treatment, we applied two acoustic shock wave therapy passes with the following parameters: 2.4 Bar, 14 Hz, 2200 total shots. The patient did not report side effects and noticed an analgesic effect during acoustic shock wave therapy. She came to her follow-up appointment one month after the session. The lesion had almost completely disappeared, and the patient was very satisfied with the results and decided to discontinue the treatment (Figure 4).



**Figure 3:** a: A professional monochromatic black tattoo on the right side of the anterior forearm; b: The immediate end point after picosecond laser treatment; c: The same lesion one month after 3 combined sessions of picosecond laser and acoustic shock wave.



**Figure 4:** a: A professional monochromatic red tattoo on the left side of the anterior thigh; b: The immediate end point after 694 nm nanosecond and 532 nm picosecond laser treatment; c: The same lesion one month after 1 single session of combined nanosecond/picosecond laser and acoustic shock wave.

## Discussion

Since the elucidation of the concept of selective photothermolysis [8], quality-switched lasers have been considered the gold standard for laser tattoo removal. The laser tattoo removal process results from selective photothermolysis and a photoacoustic effect to produce targeted destruction of tattoo pigment. Although these lasers effectively clear tattoos and have a good safety profile, certain limitations exist while targeting the exogenous pigment [9]. Incomplete clearance, long total treatment duration with the large interval between sessions, ink retention despite multiple sessions, treatment-associated side effects such as blistering and dyschromia are the main factors that limit the efficacy of laser tattoo removal [9]. The particles of black and colored tattoos in the skin may show various particle structures and sizes that influence any interaction with light. In particular, when heated up by laser radiation, such variations may lead to different fragmentation mechanisms and efficacies [10].

In order to reduce the number of sessions needed and shorten the total duration of treatment time, different techniques were developed.

The R20 method of tattoo removal is based on the principle of repeated exposure of laser light in a single session. Kossida et al. used a novel technique in which they delivered four laser passes in a single session after waiting for 20 min between each pass [11]. The mechanism of action of this method is not well known. However, it was postulated that additional laser passes could penetrate deeper into the dermis after the subsidence of frosting, thus targeting more tattoo pigment. It could also fragment tattoo ink into smaller pieces, thus allowing faster clearance by macrophages [9].

Another method to increase the efficacy of laser tattoo removal was proposed by Reddy et al., who reported the use of perfluorodecalin to reduce the frosting immediately to apply laser in quick succession without waiting for 20 min (R0 Method) [12].

Picosecond lasers have been developed, potentially offering better targeting chromophores with less damage to surrounding tissue [13]. By narrowing down the pulse duration, the peak energy of the laser beam becomes very high. Theoretical considerations assumed that pulse durations shorter than nanoseconds allow even more effective fragmentation of tattoo particles [13]. In addition, the lymphatic elimination of these finer particles is assumed to be easier, resulting in faster clearing of tattoos [9].

Tattoo treatment using a combination of pulsed Er: YAG or ultra pulsed CO<sub>2</sub> with QS Nd: YAG, also known as rapid tattoo removal technique (RTR), has been suggested to require fewer sessions compared to QS Nd: YAG laser monotherapy [14]. Besides that, a case series on a combination of QS with fractional lasers also showed improved tattoo clearance and reduced incidence of side effects compared to QS alone [15].

More recently, Acoustic Shock Wave Therapy (ASWT) has been

described to be an adjuvant in enhancing tattoo clearance. ASWT is the application of mechanically generated external sound waves [7]. The biological effects of ASWT are mediated by an increase in mediators such as vascular endothelial growth factor, which increases local blood circulation [16–18]. In addition, repeated use stimulates angiogenesis and remodeling of collagen fibers [17].

In a prospective clinical trial, Kaminer et al. demonstrated that the combination of an ASWT applied for 1 minute after a single Q-switched laser tattoo removal treatment dissipates the laser whitening and allows for additional laser passes. Enabling multiple Q-switched laser passes resulted in a statistically significant increase in tattoo fading in a single office laser tattoo removal session compared to the clinical standard single-pass Q-switched laser tattoo removal session. The authors conclude that with ASWT vacuole clearing, the loss of laser efficacy due to optical scattering is minimized, which results in more effective multi-pass Q-switched laser tattoo removal in a single office treatment session [6].

Vangipuram et al. reported accelerated tattoo removal with ASWT in conjunction with a picosecond laser and perfluorodecalin patch. The authors presented a case of 80% tattoo clearance with acoustic shock wave therapy in a patient with a 6-year-old professional black tattoo compared with 60% clearance with the picosecond 1064 nm Nd: YAG laser and perfluorodecalin patch alone. They hypothesize that acoustic shock wave therapy may enhance tattoo clearance by increasing lymphatic drainage and increasing metabolic activity in the treated area, thereby accelerating the clearance of dermal pigment vacuoles produced by the picosecond laser [7].


The physical mechanisms for laser-tattoo interactions and the tattoo particle break-up process are still not well understood. To investigate these mechanisms, Ho et al. demonstrate via computer simulations that the laser breaks up tattoo particles mainly utilizing photoacoustic, and for the same amount of laser energy, a shorter pulse is more efficient [19]. However, these presumptions disregard the second major effect that plays a crucial role in tattoo removal: the transportation of fragmented pigment particles. The transportation of the particle fragments away from the skin into the human body is assumed to cause the fading of the tattoo color. However, this process is relatively unexplored so far [13].

The atomic theory of Physicist Ernest Rutherford envisioned the atom as a miniature solar system, with electrons orbiting around a nucleus, much like planets revolving around the sun. This model described the atom as a tiny, dense, positively charged core called the nucleus, in which nearly all the mass is concentrated, around which the light, negative constituents, called electrons, circulate at some distance [20].

The photoacoustic effect during laser tattoo removal can be heard when the laser beam aims at the nucleus of the ink particles.

As the time exposure to the radiated energy progresses, it is possible to listen to how this sound becomes weaker, meaning that the photoacoustic effect is reduced. ASWT breaks this electromagnetic field created around the ink particles and allows

the photoacoustic effect to occur again. Therefore, this permits the laser to continue the micronization of the ink particles on site. This effect can be observed under dermoscopy (Figure 5).



**Figure 5:** a: Dermoscopic image of the tattoo immediately after being treated with laser only; b: Dermoscopic image of the tattoo immediately after being treated with laser and ASWT. Notice the lack of visible tattoo pigment.

### Conclusions

Acoustic Shock Wave Therapy is a safe and novel adjuvant therapy that may enhance and accelerate picosecond laser tattoo removal of both monochromatic and polychromatic tattoos. This combination approach may reduce the total number of sessions required and the waiting time in between sessions, leading to improved convenience and efficiency and increased satisfaction for both patients and clinicians. Following the reviewed literature, we believe that ASWT may improve tattoo clearance by increasing lymphatic drainage and increasing metabolic activity in the treated area, thereby accelerating the clearance of dermal pigment vacuoles. Also, we suggest that ASWT break the electromagnetic field created around the tattoo ink particles during laser treatment and allow the photoacoustic effect to occur again. In our four cases, an analgesic effect of the ASWT was observed. Further studies with a larger number of patients are necessary to demonstrate the efficacy and safety of this combination treatment approach for tattoo removal.

### Conflict of Interests

None of the authors has financial conflict of interest related to this manuscript.

### References

- Manchester GH. Tattoo removal. A new simple technique. *Clif Med.* 1973;118(3):10–12.
- Mercer NS, Davies DM. Tattoos. *BMJ.* 1991;303(6799):380.
- Korman J. Removal of gang-related tattoos. *West J Med.* 1995;162(6):541.
- Torbeck RL, Schilling L, Khorasani H, Dover JS, Arndt KA, Saedi N. Evolution of the picosecond laser: A Review of literature. *Dermatol Surg.* 2019;45(2):183–194.
- Ross V, Naseef G, Lin G, Kelly M, Michaud N, Flotte TJ, et al. Comparison of responses of tattoos to picosecond and nanosecond Q-switched neodymium: YAG lasers. *Arch Dermatol.* 1998;134(2):167–171.
- Kaminer MS, Capelli CC, Sadeghpour M, Ibrahim O, Honda LL, Robertson DW. Increased Tattoo Fading in a Single Laser Tattoo Removal Session Enabled by a Rapid Acoustic Pulse Device: A Prospective Clinical Trial. *Lasers Surg Med.* 2020;52(1):70–76.
- Vangipuram R, Hamill SS, Friedman PM. Accelerated tattoo removal with acoustic shock wave therapy in conjunction with a picosecond laser. *Lasers Surg Med.* 2018;50(9):890–892.
- Anderson RR, Parish JA. Selective photothermolysis: precise microsurgery by selective absorption of pulsed radiation. *Science.* 1983;220(4596):524–527.
- Shah SD, Aurangabadkar SJ. Newer trends in laser tattoo removal. *J Cutan Aesthet Surg.* 2015;8(1):25–29.
- Bäumler W. Laser Treatment of Tattoos: Basic Principles. *Curr Probl Dermatol.* 2017;52:94–104
- Kossida T, Rigopoulos D, Katsambas A, Anderson RR. Optimal tattoo removal in a single laser session based on the method of repeated exposures. *J Am Acad Dermatol.* 2012;66(2):271–277.
- Reddy KK, Brauer JA, Anolik R, Bernstein L, Brightman L, Hale E, et al. Topical perfluorodecalin resolves immediate

- whitening reactions and allows rapid effective multiple pass treatment of tattoos. *Lasers Surg Med.* 2013;45(2):76–80.
13. Bäumler W, Weib KT. Laser assisted tattoo removal - state of the art and new developments. *Photochem Photobiol Sci.* 2019;18(2):349–358.
  14. Sardana K, Ranjan R, Kochhar AM, Mahajan KG, Garg VK. A rapid tattoo removal technique using a combination of pulsed Er: YAG and Q-switched Nd: YAG in a split lesion protocol. *J Cosmet Laser Ther.* 2015;17(4):177–183.
  15. Weiss ET, Geronemus RG. Combining fractional resurfacing and Q-switched ruby laser for tattoo removal. *Dermatol Surg.* 2011;37(1):97–99.
  16. Yip HK, Chang LT, Sun CK, Youssef AA, Sheu JJ, Wang CJ. Shock wave therapy applied to rat bone marrow-derived mononuclear cells enhances formation of cells stained positive for cd31 and vascular endothelial growth factor. *Circ J.* 2008;72(1):150–156.
  17. Kuhn C, Angehrn F, Sonnabend O, Voss A. Impact of extracorporeal shock waves on the human skin with cellulite: A case study of an unique instance. *Clin Interv Aging.* 2008;3(1):201–210.
  18. Mittermayr R, Hartinger J, Antonic V, Meisl A, Pfeifer S, Stojadinovic A, et al. Extracorporeal shock wave therapy (eswt) minimizes ischemic tissue necrosis irrespective of application time and promotes tissue revascularization by stimulating angiogenesis. *Ann Surg.* 2011;253(5):1024–1032.
  19. Ho DD, London R, Zimmerman GB, Young DA. Laser-tattoo removal—a study of the mechanism and the optimal treatment strategy via computer simulations. *Lasers Surg Med.* 2002;30(5):389–397.
  20. Badash L. Ernest Rutherford [Internet]. Chicago: Encyclopedia Britannica, Inc; 2021.